

**RESENTING CLINICAL SIGNS**

History: Presented to ER for coughing. No history of murmur, but possible grade 1-2/6 murmur auscultated. Started on furosemide 10 mg BID, enalapril 2.5 mg BID, and pimobendan (1.25 mg BID). Also receives insulin for diabetes.

**DATE**

12/22/21

**ECHOCARDIOGRAPHIC FINDINGS**

**PERFORMED BY:**

2D, M-mode, and Doppler study.

Dr. G. Ferrer

Left atrial size is normal. The mitral valve is normal. Left ventricular dimensions are normal. Left ventricular systolic function is hyperdynamic. The aorta and aortic valve are normal. Right atrial and right ventricular dimensions are normal. The tricuspid valve is normal. The pulmonary artery and pulmonic valve are normal. No shunting lesions are visualized. No pericardial effusion or cardiac masses are seen.

**INTERPRETED BY**

Keith Blass, DVM,  
MS, DACVIM  
(Cardiology)

ECG during echo: Sinus rhythm

**PATIENT**

Pucho Dalmau

LA - 23.8 mm  
LA/Ao - 1.38  
LVIDd - 22.2 mm  
LVIDs - 9.7 mm  
FS - 56%  
RA - 16.0 mm  
LVOT - 1.06 m/s  
RVOT - 1.20 m/s

**SPECIES**

Canine

**ASSESSMENT/RECOMMENDATIONS**

Normal echocardiogram

**BREED**

Pug Mix

This examination demonstrates no evidence of structural heart disease. As such, there does not appear to be a cardiac contribution to Pucho's cough.

Thoracic radiographs are recommended to evaluate Pucho's cough if not already performed.

**SEX**

No cardiac therapy appears to be warranted based on this exam.

**MN**

A recheck echocardiogram is recommended if new physical exam and/or clinical abnormalities suggestive of cardiac dysfunction develop.

**AGE**

12 y

**WEIGHT**

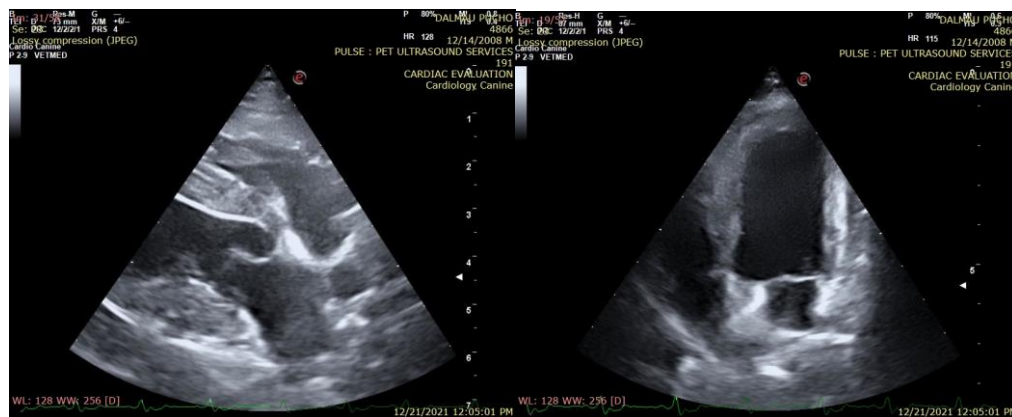20 lb

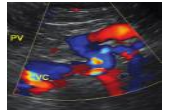
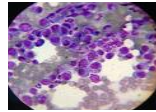
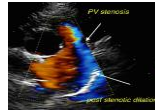
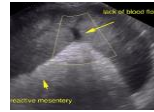
**HOSPITAL NAME**

Paseos VC

**REFERRING VET**

Dr. Ortiz





The information and recommendations provided are based on the images presented by the referring veterinarian. No evaluation can be communicated regarding pathology that was not visible in the image/video clips provided.

**DATE**

12/22/21

Thank you for this referral. If the clinical or image interpretation does not parallel your findings or if I can be of any further assistance please contact me.

**PERFORMED BY:**

Dr. G. Ferrer

**Keith Blass, DVM, MS, DACVIM (Cardiology)**  
KeithBlass@gmail.com  
631-804-5754

**INTERPRETED BY**

Keith Blass, DVM,  
MS, DACVIM  
(Cardiology)

**PATIENT**

Pucho Dalmau

**SPECIES**

Canine

**BREED**

Pug Mix

**SEX**

MN

**AGE**

12 y

**WEIGHT**

20 lb

**HOSPITAL NAME**

Paseos VC

**REFERRING VET**

Dr. Ortiz